

## OVERVIEW

- **Congenital alpha-mannosidosis in belted Galloway calves.**
- **Bovine adenovirus infection suspected to be the cause of fatal enteritis in a weaned beef calf.**
- **Cold weather-related plant poisoning incidents.**

## GENERAL INTRODUCTION

Mean temperatures were 1.4 °C below average, with this being the coldest December since 2010. Rainfall was below average in the west with an overall figure of 79 per cent. Sunshine figures were close to average at 105 per cent.

### DISEASE ALERTS

The following conditions were reported by SRUC VS disease surveillance centres in March 2022. Given similar climatic and production conditions, they could also be important this year.

#### **Listeriosis risk from feeding poor quality silage to sheep.**

A high soil content, poor fermentation, and/or exposure to air favour multiplication of *Listeria* spp. in silage. Localisation of *Listeria* spp. in the abomasal or intestinal wall can result in diarrhoea within two days of ingestion. Foetal infection with *Listeria* spp. can occur at any stage of gestation and abortion occurs from seven days post infection. Damage to the buccal mucosa allows *L. monocytogenes* to enter and ascend to the brainstem via the trigeminal nerve. This accounts for the appearance of neurological signs typical of listerial encephalomyelitis 10 to 21 days after poor quality, mouldy or spoiled silage is fed.

#### **Hypoglycaemic encephalopathy in neonatal lambs secondary to ewe energy deficiency.**

Affected lambs can be stillborn or born live but weak. They may appear dull, ataxic or recumbent and can exhibit tremor. Triplet lambs are most at risk and the severity of clinical signs can vary between siblings. Signs often improve or resolve after a few days of nursing. Dams of affected lambs should be blood sampled within 24 hours of parturition as betahydroxybutyrate levels above the reference range at this stage confirm the diagnosis. Brain histopathology on the lambs can also be diagnostic.

## CATTLE

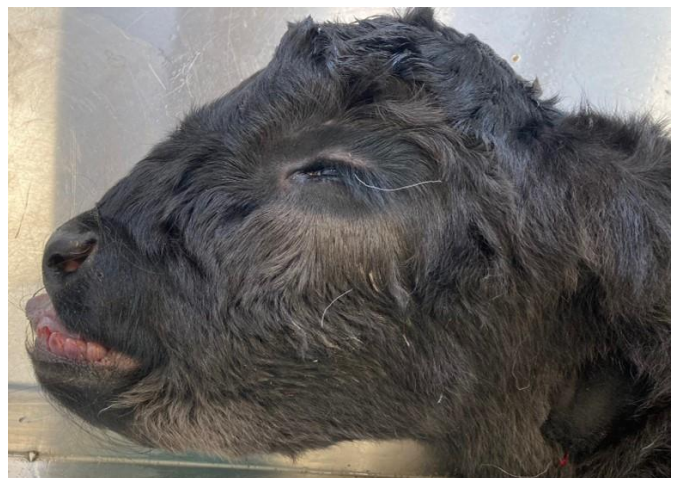### Toxic conditions

The third 16-month-old Holstein heifer to be found dead at grass was submitted for postmortem examination. Six or seven pieces of pale yellow to white root consistent with hemlock water dropwort (*Oenanthe crocata*) were found within the rumen. The plant was later identified growing in ditches around the field margins.

### Generalised and systemic conditions

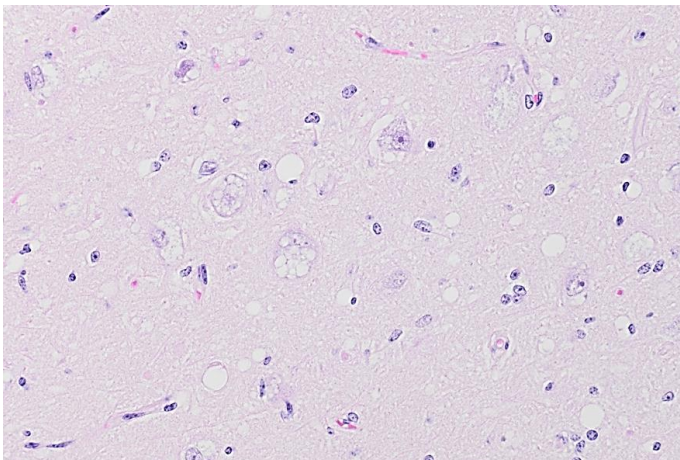
A dairy herd reported problems with milk drop and diarrhoea which had resolved in most cases. However, a late dry cow with diarrhoea continued to deteriorate and was euthanased for postmortem examination after failing to respond to treatment. Significant findings included healing udder cleft dermatitis, pale yellow renal cortices and carcass oedema. Antemortem biochemistry had revealed hypoalbuminaemia (11 g/l, reference range 30-40 g/l) and azotaemia (urea 28.6 mmol/l, (reference range 3-8 mmol/l); creatinine 261 µmol/l (reference range <=180 µmol/l)). Histopathology confirmed a diagnosis of renal amyloidosis, and it was suggested that the udder cleft dermatitis could have acted as a focus of chronic inflammation and predisposed to amyloid deposition. This case was not considered representative of the herd problem.

Congenital alpha-mannosidosis was diagnosed in six belted Galloway calves born in a herd of 31 cows. A range of malformations were observed including brachygnathia superior (Fig 1), doming of the head, arthrogryposis, ascites and internal hydrocephalus.



**Figure 1 – Brachygnathia superior in a belted Galloway calf with congenital alpha-mannosidosis**

Histopathology revealed clear cytoplasmic microvacuolation within neurones (Fig 2), hepatocytes, renal tubular epithelium, and thyroid follicular epithelial cells. These findings are typical of a lysosomal storage disease, and genetic testing on two of the calves confirmed that both were homozygous for the genetic mutation causing alpha-mannosidosis. This condition has an autosomal recessive mode of inheritance and has previously been well described in Galloway and Aberdeen Angus cattle.<sup>1</sup> It causes an inherited deficiency of the enzyme alpha mannosidase resulting in storage of water-soluble oligosaccharides within vesicles. Clinical signs can vary from stillbirth to severe congenital neurological disease. Calves that survive the neonatal period can exhibit progressive ataxia, head tremor and aggression. In this case the affected calves were stillborn or died a few hours after birth. A new young bull had been used for the first time in 2022 along with an old bull previously used in 2020 and 2021. Affected calves were sired by both bulls. All of the old bull's calves had survived but there had been two stillbirths in 2020 that were assumed to be a result of dystocia and not investigated.



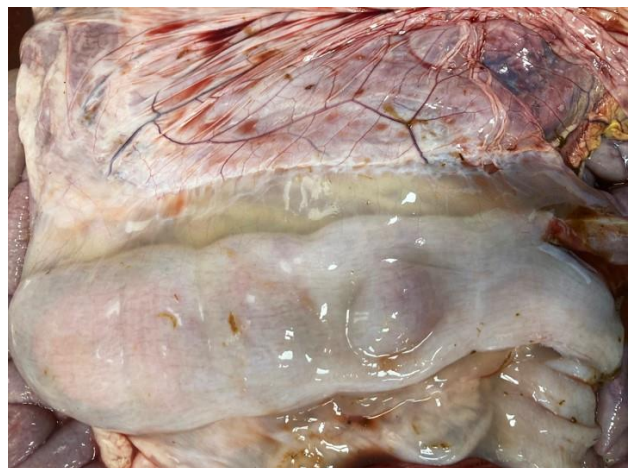**Figure 2 – Neuronal cytoplasmic vacuolation typical of a lysosomal storage disease**

### Alimentary tract disorders

A three-week-old Holstein cross calf was submitted for postmortem examination with a history of pasty diarrhoea, weakness and recumbency prior to death. Three animals had died with similar clinical signs. Calves were housed in pairs and bucket fed two litres of milk replacer twice a day. The amount of powder used had been increased from 125 to 150 g/litre during the cold weather, and it was reported that the water in the shed was freezing intermittently. The rumen and abomasum both contained unclotted milk and faeces were liquid. Small numbers of cryptosporidial oocysts were the only enteropathogen detected. Histopathology identified a purulent rumenitis consistent with rumen

drinking and acidosis, abomasal and intestinal dysbiosis, and infection with attaching and effacing *Escherichia coli*. SRUC VS commented that the cold temperatures may have affected feeding behaviour and milk temperature increasing the likelihood of rumen drinking. Additionally, although the concentration of milk replacer had been increased, feeding 2 litres twice a day is insufficient. This can also predispose to rumen drinking as well as impacting on growth rates and immune function.

A six-month-old salers calf died within an hour of being found recumbent and was submitted for postmortem examination. It was the only death from a group of 50 weaned calves at grass with access to hay and a barley blend. The abomasum was diffusely reddened and moderately thickened, with petechial haemorrhages on the mucosa. The large intestinal content was very watery with reddening of the mucosa, a few small punctuate ulcers in the colon, and prominent mesocolon oedema (Fig 3). Histopathology revealed frequent intranuclear viral inclusion bodies within the endothelia of blood vessels in the mucosa and submucosa of the abomasum, small and large intestines. Damage to the endothelia explained the mesocolon oedema, and the presence of inclusion bodies suggested infection with bovine adenovirus. A confirmatory test is not readily available, but the findings were similar to those described in cases of adenovirus enteritis in New Zealand cattle.<sup>2</sup> Affected animals are typically pyrexic and diarrhoeic and may die peracutely. Bovine adenoviruses are widespread in the environment but given the low prevalence of disease it is likely that a combination of host and environmental factors are required to allow infection to become established. This calf had evidence of moderate parasitic gastroenteritis and mild coccidiosis, both of which may have predisposed to adenoviral infection but are not uncommon findings in young cattle.



**Figure 3 – Mesocolon oedema secondary to suspected adenovirus infection**

A video of an 18-month-old Limousin cross male beef finisher was received prior to euthanasia and submission of the carcass. The animal had been recumbent for 24 hours and was bright and responsive but unable to rise due to paresis of all four legs. Postmortem examination detected a pale bulbous Y-shaped mass in the cervical spinal column adjacent to the axis (Fig 4). Further dissection found that it was adherent to the dura mater and causing a focal depression in the spinal cord. Histopathology and immunohistochemistry confirmed that the mass was a lymphoma of T-cell origin and therefore consistent with sporadic juvenile lymphoma. Infiltration of the prescapular lymph node by neoplastic cells indicated that it was multicentric. Characterisation of the tumour was important as spinal involvement is well recognised in cases of enzootic bovine leukosis associated with bovine leukaemia virus infection. This notifiable condition is most common in animals over two years-of-age and is a result of B-cell proliferation.



**Figure 4 – Spinal neoplasia in a case of sporadic juvenile lymphoma**

## SMALL RUMINANTS

### Nutritional and metabolic disorders

120 Texel cross store lambs that had been purchased from the same source in late September were stocked on rape for one month without any issues. The fence was moved weekly when only stalks remained. Six animals (5 per cent) were found dead within a 36-hour period and clostridial disease was suspected as the lambs were unvaccinated. Concentrate pellets fed from a hopper had been introduced one week earlier but uptake was reported to be low. No deaths occurred in the smaller lambs stocked on grass. Postmortem examination of a fresh carcass found that the rumen was well filled with both forage and cereal grains visible. A sweet smell was noted, but a rumen pH of 6.1 suggested that acidosis was not the cause of death. Faeces were diarrhoeic but there was no significant worm burden and testing for epsilon toxin proved negative. Histopathology failed to detect any evidence of clostridial disease but revealed a severe acute to sub-acute rumenitis consistent with acidosis as the cause of death. Rumen acidosis was

also diagnosed on three other holdings during December with lamb losses at the time of submission ranging from 2 to 12 per cent. Rumen pH values in these cases varied from 3.8 to 4.5 which is more typical. It is difficult to control the intakes of individual lambs when supplementary feeding is introduced, particularly when fed via a hopper. The wintery conditions may have heightened the risk of acidosis by increasing the lambs' reliance on concentrate feed.

### Toxic conditions

One ewe and three tups from a group of 150 died following a period of lethargy and anorexia progressing to recumbency. Five other animals were reported to be ill and the carcasses of a mule ewe and a Texel tup were submitted to investigate the problem. Large numbers of partly chewed *Rhododendron* sp. leaves were found within the forestomachs confirming plant toxicity as the cause of death. The surviving animals were removed from the field. The carcass of a Scottish blackface gimmer from a second holding was found to have *Pieris* sp. leaves in the rumen. Three animals had died and two others were ill. Freezing conditions at the time of submission were considered to have caused the sheep to seek alternative sources of forage. Field boundaries should be checked for the presence of potentially poisonous plants and supplementary forage should be provided when adverse weather is forecast.

## PIGS

### Circulatory system disorders

Two 17-week-old gilts were submitted to investigate the cause of four sudden deaths over a 24-hour period in the 70-100 kg group on a 3000 animal, breeding to finishing unit. Postmortem examination revealed fibrinous pericarditis, endocarditis affecting one or both atrio-ventricular valves and evidence of cardiac failure. *Erysipelas rhusiopathiae* was isolated from the affected heart valves. The pigs were reported to have received an erysipelas vaccination which would be expected to prevent outbreaks of disease. However, there was a possibility that this batch of gilts had been missed.